

Endometrial Cancer

Richard S. Pieters, MD
Maryanne Bombaugh, MD
Yuxin Liu, MD, PhD
Gina Cunto-Amesty, MD
Adib R. Karam, MD
Elizabeth Kurian, MD
Sarah Hughes, MD



Citation: Pieters RS, Bombaugh M, Liu Y, Cunto-Amesty G, Karam AR, Kurian E, Hughes S. Endometrial Cancer. In: Pieters RS, Liebmann J, eds. *Cancer Concepts: A Guidebook for the Non-Oncologist*. Worcester, MA: University of Massachusetts Medical School; 2014. doi: http://dx.doi.org/10.7191/cancer_concepts.1013.

Copyright: All content in *Cancer Concepts: A Guidebook for the Non-Oncologist*, unless otherwise noted, is licensed under a Creative Commons Attribution-Noncommercial-Share Alike License, <http://creativecommons.org/licenses/by-nc-sa/4.0/>

Notes & Additional Reading

Summary and Key Points

1. Adenocarcinoma of the endometrium is the most common gynecologic malignancy in the United States.
2. Because abnormal vaginal bleeding is a common initial symptom of endometrial cancer, most cancers are discovered at an early stage.
3. Endometrial adenocarcinoma is associated with a variety of risk factors, many of which are marked by a state of elevated or prolonged exposure to estrogens.
4. Lower grade, or Type 1, endometrial cancers are most strongly associated with excessive estrogen exposure.
5. Higher grade, or Type 2, endometrial cancers have a greater risk of relapse or systemic spread than Type 1 tumors.
6. Surgical resection, a hysterectomy and removal of the ovaries plus/minus pelvic and paraaortic lymphadenectomy, is the foundation of treatment of endometrial cancer. Patients at high risk for local/regional recurrence receive adjuvant radiotherapy. Medically inoperable patients receive primary radiotherapy and or hormonal therapy.
7. Sarcomas of the uterus also occur, but are uncommon. Leiomyosarcomas are aggressive tumors, and endometrial stromal sarcomas are likely to behave in an indolent fashion.
8. Serous and clear cell carcinomas are rare but aggressive type of endometrial cancer.

Epidemiology

Endometrial adenocarcinoma is the most common gynecologic malignancy in the United States and the fourth most common malignancy in women overall. The American Cancer Society (ACS) data for endometrial cancer in the United States estimates that more

Endometrial Cancer

Richard S. Pieters, MD
Maryanne Bombaugh, MD
Yuxin Liu, MD, PhD
Gina Cunto-Amesty, MD
Adib R. Karam, MD
Elizabeth Kurian, MD
Sarah Hughes, MD



than 46,000 new cases occurred in 2011.¹ Endometrial cancer causes approximately 7,310 deaths each year, and is the eighth leading site of cancer related deaths among American women.²

Risk Factors

Risk factors are well described for this cancer, and knowledge of these risk factors can contribute to early diagnosis and treatment. Many of these risks are conditions causing elevated estrogen levels or unusual duration of estrogen exposure, particularly [unopposed estrogen exposure](#). These include [polycystic ovary disease](#), granulosa cell tumor (benign estrogen producing tumor), [nulliparity](#), infertility, which is associated with anovulatory cycles, prolonged unopposed post-menopausal hormone use, early menarche and late menopause, greater than 2 years of Tamoxifen use and obesity. Other factors increasing risk include being over 50, of white race and having diabetes mellitus, hypertension, cholecystitis, and thyroid disease.

Surprisingly, intentional weight loss does not appear to be associated with decreased risk. On the other hand, regular physical exercise does appear to be associated with a decreased risk. Parity also decreases risk of endometrial cancer, as does extended lactation; breastfeeding longer than 18 months decreases risk by 20%. Of course, hysterectomy prevents endometrial cancer except the rare case of endometrial cancer arising in endometriosis, which can occur many years after hysterectomy.³

Diagnosis

Clinically, most women with endometrial adenocarcinoma present with vaginal bleeding and discharge. Although postmenopausal

Endometrial Cancer

Richard S. Pieters, MD
Maryanne Bombaugh, MD
Yuxin Liu, MD, PhD
Gina Cunto-Amesty, MD
Adib R. Karam, MD
Elizabeth Kurian, MD
Sarah Hughes, MD



bleeding can be due to several benign etiologies such as endometrial atrophy, endometrial polyps, submucosal fibroids and endometrial hyperplasia, it should always be worked-up to exclude the possibility of endometrial adenocarcinoma. Pelvic ultrasound is the imaging modality of choice for the initial evaluation of the endometrium in patients presenting with postmenopausal bleeding, as well as women with risk factors for endometrial cancer presenting with menstrual cycle irregularities or heavy menstrual bleeding. The endometrial thickness on transvaginal ultrasound must always be correlated with the patient's age and the stage of the menstrual cycle. In women with active menstrual cycle the endometrial thickness can reach up to 14 mm. In a postmenopausal patient, endometrial thickness less than 4 mm on transvaginal US generally excludes endometrial cancer⁴; any abnormal endometrial thickness should be further investigated by hysteroscopy and/or endometrial biopsy. (Figure 1).

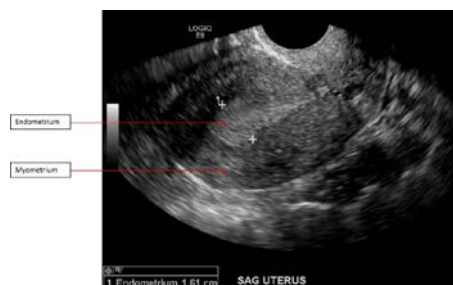

Figure 1. 54-year-old female patient presenting with postmenopausal vaginal bleeding. Sagittal image from a transvaginal ultrasound reveals a thickened endometrium measured at 1.61 cm (between calipers). The myometrium is normal. Biopsy confirmed endometrial carcinoma. Courtesy of University of Massachusetts Medical School, Abdominal Imaging Division, UMass Memorial Medical Center.

Almost 3/4^{ths} of endometrial adenocarcinomas are Stage I when diagnosed. These women have an excellent prognosis. Only about

Endometrial Cancer

Richard S. Pieters, MD
Maryanne Bombaugh, MD
Yuxin Liu, MD, PhD
Gina Cunto-Amesty, MD
Adib R. Karam, MD
Elizabeth Kurian, MD
Sarah Hughes, MD



3% of these cancers are Stage IV at diagnosis. In addition to personal and clinical factors, there are two other entities that contribute to the epidemiology of endometrial cancer: genetic risk and atypical endometrial hyperplasia.

Genetic risk for endometrial adenocarcinoma: The most common manifestation of hereditary nonpolyposis colorectal cancer (Lynch Syndrome) in women is endometrial cancer (40-60% lifetime risk) followed by colon cancer and then ovarian cancer. Individuals from these families are at risk of many other cancers, including stomach, pancreas, kidney/ureter, hepatobiliary tract, prostate, ovaries, gall bladder duct, brain, small intestine, breast and the skin.⁵

Atypical endometrial hyperplasia is considered a precursor lesion to endometrial cancer. Endometrial hyperplasia occurs as a continuum from simple to complex (Figure 2), and may progress to an invasive endometrial cancer if left untreated.⁶ Atypical endometrial hyperplasia is usually treated with a hysterectomy, unless a woman desires childbearing in which case progestin therapy and close monitoring is offered. When childbearing is completed a hysterectomy is usually recommended.⁷

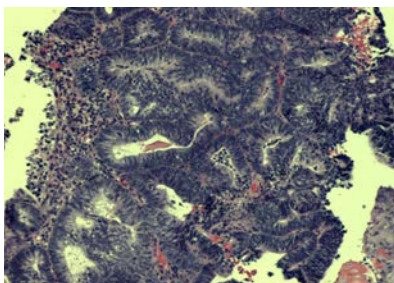
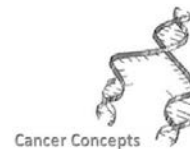


Figure 2. This image shows mostly endometrial complex hyperplasia with only few foci of well differentiated adenocarcinoma, endometrioid type. The hyperplastic glands are tightly crowded, but still separate from each other by a very thin strand of stromal tissue. In the adenocarcinoma foci we start

Endometrial Cancer

Richard S. Pieters, MD
Maryanne Bombaugh, MD
Yuxin Liu, MD, PhD
Gina Cunto-Amesty, MD
Adib R. Karam, MD
Elizabeth Kurian, MD
Sarah Hughes, MD



observing glands within glands and areas showing [cribriforming pattern](#) of growth. Courtesy of University of Massachusetts Medical School, Abdominal Imaging Division, UMass Memorial Medical Center.

Histological Types Of Endometrial Cancer

Cancers of the uterus originate from either (1) the endometrium, or lining of the uterus, and are called **carcinomas** or (2) the uterine muscle or connective tissues which are called sarcomas.

The most common histological type of endometrial carcinoma is the adenocarcinoma, which arises from the glandular lining of the uterus. Eighty percent (80%) of endometrial adenocarcinomas are the *endometrioid* type and consist of glandular cells that resemble those of the uterine lining. (Figures 3 & 4). If the adenocarcinoma contains squamous cells it is called an *adenocarcinoma with squamous differentiation*. (Figure 5). The grade of the cancer is determined by the grade of the adenomatous component.

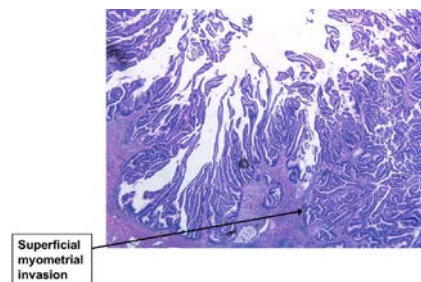


Figure 3. Endometrioid Adenocarcinoma, Grade 1. This grade endometrioid adenocarcinoma shows villoglandular growth pattern. The tumor superficially invades into the underlying myometrium. Courtesy of University of Massachusetts Medical School, Department of Pathology, UMass Memorial Medical Center.

Endometrial Cancer

Richard S. Pieters, MD
Maryanne Bombaugh, MD
Yuxin Liu, MD, PhD
Gina Cunto-Amesty, MD
Adib R. Karam, MD
Elizabeth Kurian, MD
Sarah Hughes, MD

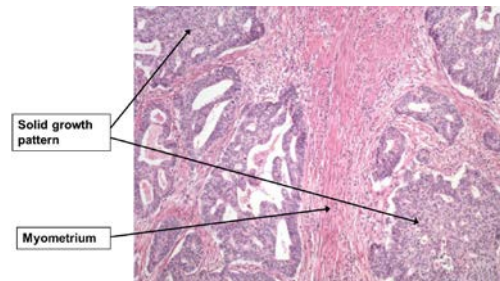


Figure 4. Endometrioid Adenocarcinoma with Myometrial Invasion, Grade 2. A section taken from the endometrial mass shows many neoplastic glands invade deep into the myometrium. Because these glands resemble normal proliferative endometrial glands, this type of cancer is called endometrioid type. On the other hand, these glands are malignant, not benign, mainly because of their complex architecture and infiltrating growth pattern. Endometrioid adenocarcinoma is the most common type of endometrial carcinoma. It is estrogen-dependent, which is also known as “type I” endometrial cancer. Courtesy of University of Massachusetts Medical School, Department of Pathology, UMass Memorial Medical Center.

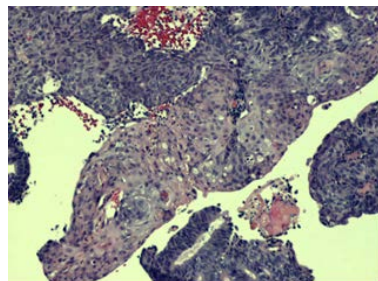


Figure 5. In the center, a focus of squamous metaplasia is present. Such areas are discounted when the percentage of the solid component of the adenocarcinoma is estimated for tumor grading purposes. Courtesy of University of Massachusetts Medical School, Department of Pathology, UMass Memorial Medical Center.

The remaining non-endometrioid endometrial adenocarcinomas are the *clear-cell carcinoma* (Figure 6), *serous carcinoma* (also called papillary serous carcinoma) (Figures 7 & 8), and *poorly differentiated carcinoma*.

Endometrial Cancer

Richard S. Pieters, MD
Maryanne Bombaugh, MD
Yuxin Liu, MD, PhD
Gina Cunto-Amesty, MD
Adib R. Karam, MD
Elizabeth Kurian, MD
Sarah Hughes, MD

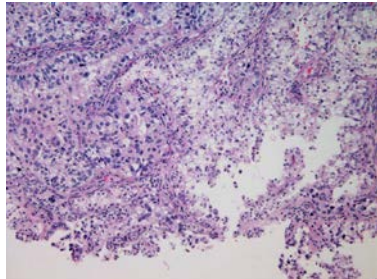


Figure 6. Clear cell carcinoma: Type II tumor. Patients tend to be older than those with endometrioid adenocarcinoma. These are biologically aggressive tumors with a worse prognosis than endometrioid adenocarcinoma. Courtesy of University of Massachusetts Medical School, Department of Pathology, UMass Memorial Medical Center.

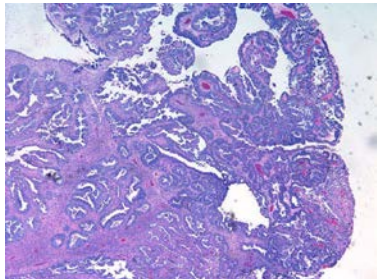


Figure 7. Uterine Serous Carcinoma. Type II endometrial cancer is estrogen-independent. An example is endometrial serous carcinoma. Endometrial serous carcinoma is composed of highly malignant cells growing around a fibrovascular core. Numerous mitoses are present. This is a highly aggressive endometrial cancer and commonly seen in elderly patients. Courtesy of University of Massachusetts Medical School, Department of Pathology, UMass Memorial Medical Center.

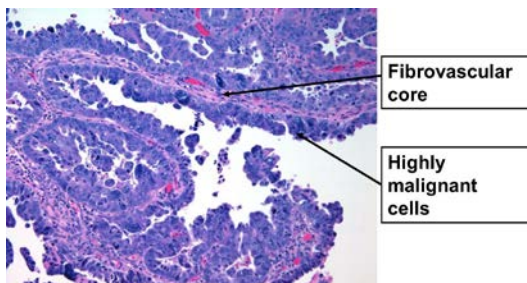
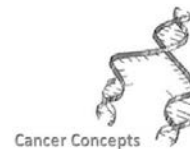


Figure 8. Uterine serous carcinoma. Courtesy of University of Massachusetts Medical School, Department of Pathology, UMass Memorial Medical Center.

Endometrial Cancer

Richard S. Pieters, MD
Maryanne Bombaugh, MD
Yuxin Liu, MD, PhD
Gina Cunto-Amesty, MD
Adib R. Karam, MD
Elizabeth Kurian, MD
Sarah Hughes, MD



There is one tumor of the endometrium with unique cancer morphology, with features of both an endometrial carcinoma and a sarcoma. This tumor is called a uterine carcinosarcoma (Figures 9 & 10), also known as a malignant mixed Mullerian tumor. Although typically classified as a uterine sarcoma, it is thought that this tumor may actually be a form of poorly differentiated carcinoma because the carcinosarcoma and endometrial carcinomas are similar in how they are treated and how they spread. CS is an aggressive tumor, similar to or worse than Grade 3 adenocarcinoma with the same extent of disease.

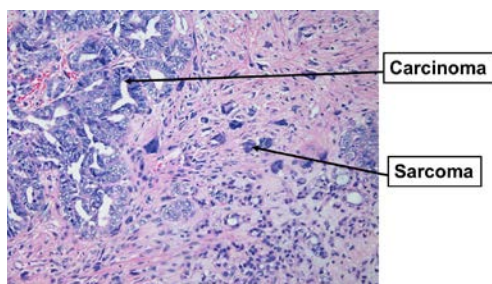


Figure 9. Uterine Carcinosarcoma. Courtesy of University of Massachusetts Medical School, Department of Pathology, UMass Memorial Medical Center.

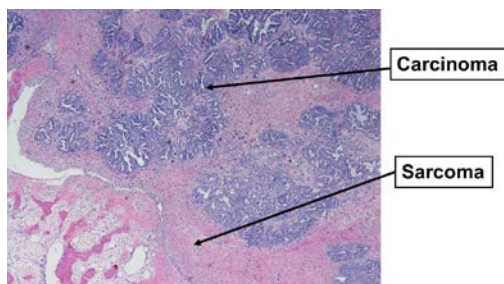
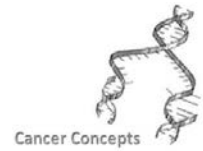

Figure 10. Uterine Carcinosarcoma. Carcinosarcoma is a biphasic tumor including carcinoma and sarcoma component. The sarcoma component can be leiomyosarcoma, stromal sarcoma, or undifferentiated sarcoma. Some cases have bone and cartilage component (left lower corner). Courtesy of University of Massachusetts Medical School, Department of Pathology, UMass Memorial Medical Center.

Endometrial Cancer

Richard S. Pieters, MD
Maryanne Bombaugh, MD
Yuxin Liu, MD, PhD
Gina Cunto-Amesty, MD
Adib R. Karam, MD
Elizabeth Kurian, MD
Sarah Hughes, MD



Endometrial Carcinoma Grading

The grading of this cancer is done on a scale of 1 to 3 based on the amount of solid growth and nuclear atypia present.

Endometrial Carcinoma Prognostic Typing

Endometrial cancers are often further categorized, based on underlying causes and prognosis, into a Type 1 or Type 2 cancer.

Type 1 is thought to be caused by excess estrogen, is usually not aggressive and is slow to metastasize or spread to contiguous tissues. Grade 1 (Figure 11) and Grade 2 endometrioid cancers (Figure 12) are examples of Type 1 endometrial cancers.

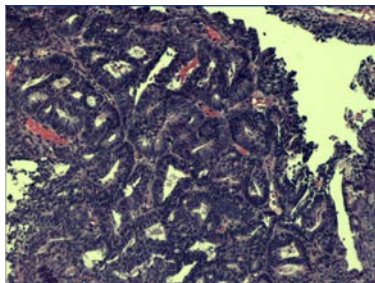


Figure 11. The well differentiated adenocarcinoma of the endometrium (endometrioid type, FIGO grade 1) typically has a similarity to the benign endometrial tissue, in the sense that the neoplastic epithelium still attempts to organize in glandular structures that resemble normal endometrial glands. Courtesy of University of Massachusetts Medical School, Department of Pathology, UMass Memorial Medical Center.

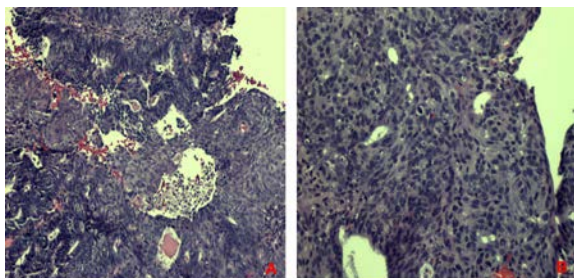


Figure 12. (Figure 12A) FIGO Grade 2. Notice that this neoplasm still has

Endometrial Cancer

Richard S. Pieters, MD
Maryanne Bombaugh, MD
Yuxin Liu, MD, PhD
Gina Cunto-Amesty, MD
Adib R. Karam, MD
Elizabeth Kurian, MD
Sarah Hughes, MD



glandular structures, but in some areas, these glands start getting confluent and form solid areas. (Figure 12B) FIGO Grade 3. Notice the almost complete lack of gland-like structures and the monotonous sheet of malignant cells. It is difficult to identify the tissue of origin. Therefore it is a poorly differentiated carcinoma. A FIGO grade 1 tumor has less than 5 % solid areas, FIGO grade 2, between 6 to 50 % of solid areas and FIGO grade 3, more than 50 % of solid areas. Courtesy of University of Massachusetts Medical School, Department of Pathology, UMass Memorial Medical Center

Type 2 endometrial cancers do not appear to be caused by estrogen excess, and they are more likely to be aggressive, metastasize, and have unfavorable prognoses. Serous carcinoma, poorly differentiated carcinoma and Grade 3 endometrioid carcinoma would be considered Type 2. Higher grade endometrioid tumors and non-endometrioid endometrial carcinomas (Type 2) are associated with higher rates of deep myometrial invasion and lymphatic spread.⁸

Uterine Sarcomas

Sarcomas comprise about 3% of uterine cancers. Technically, they are NOT endometrial cancers, since they arise from the myometrial wall. They also often present with abnormal uterine bleeding, but some tumors are found because of pelvic masses. Leiomyomas (fibroids) (Figure 13) are quite common, completely benign (Figure 14) and often resected if symptomatic (Figure 15).

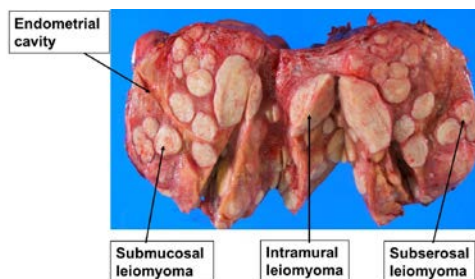


Figure 13. Uterine Leiomyomata. Leiomyoma (uterine fibroid) is a benign smooth muscle tumor. As shown in this photograph, leiomyoma is round, white, and firm nodule. The cut surface has a whorled appearance. The nodules are located at subserosal, intramural, or submucosal. Even a very

Endometrial Cancer

Richard S. Pieters, MD
Maryanne Bombaugh, MD
Yuxin Liu, MD, PhD
Gina Cunto-Amesty, MD
Adib R. Karam, MD
Elizabeth Kurian, MD
Sarah Hughes, MD



small submucosal leiomyoma can cause heavy bleeding due to compression of the endometrium. As seen in this case, the endometrial cavity is severely deformed by multiple leiomyomata. Courtesy of University of Massachusetts Medical School, Department of Pathology, UMass Memorial Medical Center.

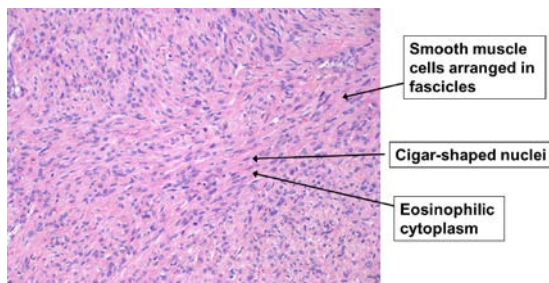


Figure 14. As seen in this H&E slide, leiomyoma is composed of spindle cells arranged in fascicles. The spindle cells have cigar-shaped nuclei and eosinophilic cytoplasm. These spindle cells are smooth muscle cells. Leiomyoma is the most common benign uterine neoplasm. The malignant counterpart is leiomyosarcoma which displays highly atypical spindle cells, necrosis, and extremely high mitotic activity. An example of leiomyosarcoma is shown in the next slide. However the classification of uterine smooth muscle tumor is very complicated. Some leiomyomas may display certain “atypical features”, such as high mitotic activity or cytological atypia. These are known as “atypical leiomyoma” or STUMP (Smooth Muscle Tumors of Uncertain Malignant Potential). As the name indicated, it is difficult to predict these tumors’ behavior and they may follow a benign or a malignant course. Courtesy of University of Massachusetts Medical School, Department of Pathology, UMass Memorial Medical Center.

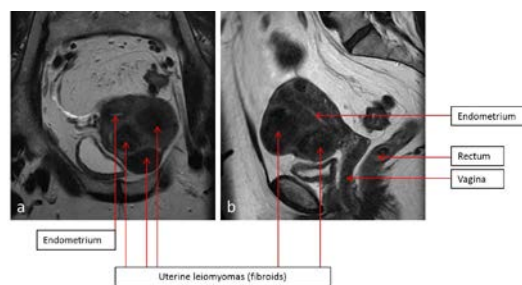


Figure 15. 49-year-old female patient with history of uterine fibroids. Coronal plane (a) and sagittal plane (b) images from pelvic MRI, demonstrate multiple uterine fibroids that were stable over four years. Courtesy of University of Massachusetts Medical School, Abdominal Imaging Division, UMass Memorial Medical Center.

But sometimes the surgeon and the patient are surprised and the

Endometrial Cancer

Richard S. Pieters, MD
Maryanne Bombaugh, MD
Yuxin Liu, MD, PhD
Gina Cunto-Amesty, MD
Adib R. Karam, MD
Elizabeth Kurian, MD
Sarah Hughes, MD



tumors are malignant (Figure 16). Leiomyosarcomas are the most common and most aggressive myometrial sarcomas, even in early stage (Figures 17 & 18). Endometrial stromal cell sarcomas have an indolent course, tend to present as Stage I, occur in younger women, and preservation of ovaries does not alter prognosis. The mainstay of treatment for both is surgery, which can be conservative and spare ovaries in young women; limited resections of uterine sarcomas with preservation of fertility have been reported. For locally advanced leiomyosarcomas, survival appears to be improved with adjuvant radiotherapy. As with other sarcomas, the lungs are the most common site of metastasis. Removal of oligometastatic disease can be associated with long term survival.⁹

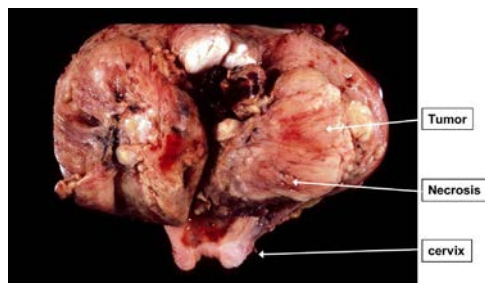


Figure 16. Uterine leiomyosarcoma. As seen in this gross picture, the uterus is deformed by a large, fresh, solid mass (8 cm in diameter). Areas of hemorrhage and necrosis are seen on the cut section. Courtesy of University of Massachusetts Medical School, Department of Pathology, UMass Memorial Medical Center.

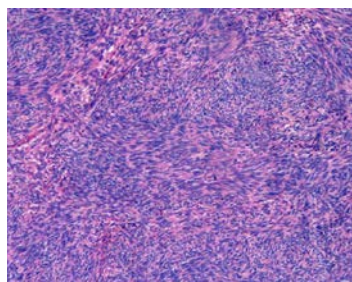


Figure 17. Compared with leiomyoma, the present tumor is highly cellular on a low power view. Courtesy of University of Massachusetts Medical School,

Endometrial Cancer

Richard S. Pieters, MD
Maryanne Bombaugh, MD
Yuxin Liu, MD, PhD
Gina Cunto-Amesty, MD
Adib R. Karam, MD
Elizabeth Kurian, MD
Sarah Hughes, MD



Department of Pathology, UMass Memorial Medical Center.

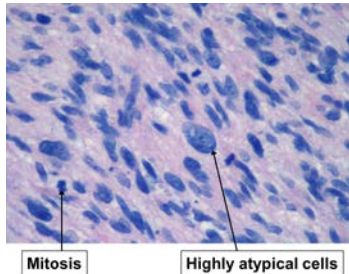


Figure 18. On high power view, the tumor is composed of highly atypical spindle cells with hyperchromatic nuclei. Numerous mitoses are seen. This is diagnostic for malignant smooth muscle tumor: leiomyosarcoma. Courtesy of University of Massachusetts Medical School, Department of Pathology, UMass Memorial Medical Center.

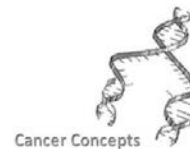
Management of Endometrial Cancer

Watch the first two and last two minutes of this YouTube movie (<https://www.youtube.com/watch?v=xHHR8oxuo1M>) of a robotic laparoscopic hysterectomy.

Once a diagnosis of endometrial cancer has been made through endometrial tissue sampling, conventional therapy begins with surgical staging that includes the removal of the uterus (including cervix) (Figure 19), fallopian tubes, and ovaries; peritoneal cytology; and intraoperative assessment of the pelvic and para-aortic lymph nodes. In select circumstances, such as when there is bulky cervical disease or if a patient cannot safely undergo surgery, radiation therapy may be given preoperatively or as the primary treatment to treat disease and control bleeding. Low grade, low volume disease patients may be treated with brachytherapy alone; larger volume disease and higher grade, with significant risk of nodal disease is usually treated with external beam treatment of the uterus and pelvic lymph nodes, followed by brachytherapy (Figures 20-23). (See

Endometrial Cancer

Richard S. Pieters, MD
Maryanne Bombaugh, MD
Yuxin Liu, MD, PhD
Gina Cunto-Amesty, MD
Adib R. Karam, MD
Elizabeth Kurian, MD
Sarah Hughes, MD



Principles of Radiation Oncology chapter). Patients with significant medical co-morbidities or with low grade/low stage endometrial cancer may be treated with external beam or even hormonal suppression alone.

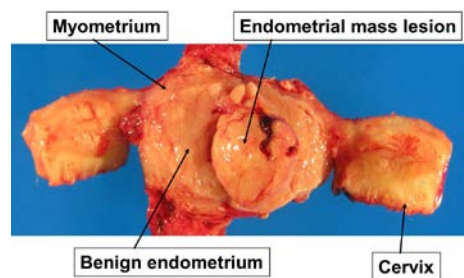


Figure 19. The uterus is opened to show the endometrial cavity. There is a mass lesion arising from the posterior endometrium and protruding into the uterine cavity. This is endometrial adenocarcinoma. The remaining endometrium is very thin and most likely benign. The myometrium and cervix are normal. Courtesy of University of Massachusetts Medical School, Department of Pathology, UMass Memorial Medical Center.

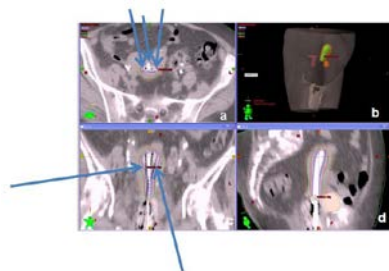


Figure 20 Brachytherapy. Uterine capsules, loaded with radioactive iridium for treatment of endometrial cancer. These are placed through the cervix to attempt to push dose out into the cornua of the cavity.

20a. Axial CT slice (arrows point at capsules), 20b. 3 dimensional treatment plan dose cloud, showing rapid fall off from sources within capsules. 20c. Coronal CT slice, (arrows point at capsules) 20d. Sagittal CT slice. Courtesy of University of Massachusetts Medical School, Department of Radiation Oncology, UMass Memorial Medical Center.

Endometrial Cancer

Richard S. Pieters, MD
Maryanne Bombaugh, MD
Yuxin Liu, MD, PhD
Gina Cunto-Amesty, MD
Adib R. Karam, MD
Elizabeth Kurian, MD
Sarah Hughes, MD

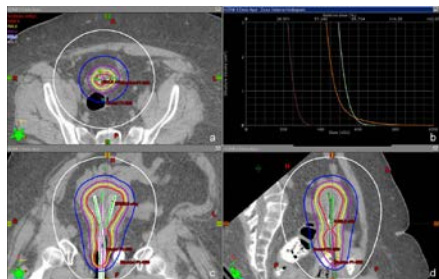
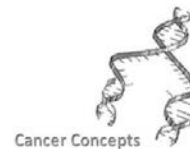


Figure 21. Endometrial Cancer High Dose Rate Applicator Tandems geometry is fixed to push tips into cornua 20b Dose volume Histogram (DVH) showing very rapid dose falloff from applicator, which protects surrounding normal structures. Courtesy of University of Massachusetts Medical School, Department of Radiation Oncology, UMass Memorial Medical Center.

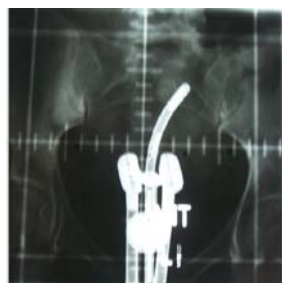

Figure 22. Fletcher Suit Delclos Uterine Low Dose Rate applicator. Loaded with radioactive cesium sources. Applicator is held in place by vaginal packing. Patient must remain in bed for 2-3 days while treatment is administered, usually twice, 1 week apart. Tandem is tube in uterus, ovoids are cylinders next to tandem, which are placed in vaginal fornices, with cervix wedged between. Dose is pushed out into uterine cavity cornua by loading a stronger source in the tip of the tandem. With this application, deviated to the left, the left side will receive more dose than the right. Courtesy of University of Massachusetts Medical School, Department of Radiation Oncology, UMass Memorial Medical Center.

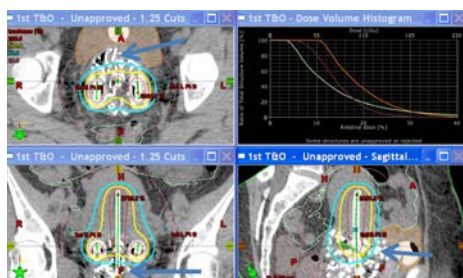


Figure 23. Brachytherapy: HDR Tandem and Ovoids. DVH demonstrates

Endometrial Cancer

Richard S. Pieters, MD
Maryanne Bombaugh, MD
Yuxin Liu, MD, PhD
Gina Cunto-Amesty, MD
Adib R. Karam, MD
Elizabeth Kurian, MD
Sarah Hughes, MD



less rapid dose falloff than is seen with capsule treatment seen in figure 20, an effect of multiple source positions in ovoids. Notice pear shaped dose distribution in coronal view (22c) Yellow lines represent 100% of prescription dose. Arrows point at vaginal packing. Courtesy of University of Massachusetts Medical School, Department of Radiation Oncology, UMass Memorial Medical Center.

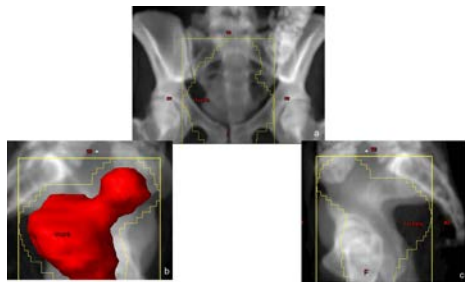


Figure 24. External Beam Fields– treatment volume inside inner yellow lines. 24a. AP pelvis field. PA field is opposed for a 4 field plan (see figure 25) 24b. Right Lateral Pelvis field with uterus in red. 24c. Left Lateral Pelvis field without uterus to show position of femoral heads in field. Courtesy of University of Massachusetts Medical School, Department of Radiation Oncology, UMass Memorial Medical Center.

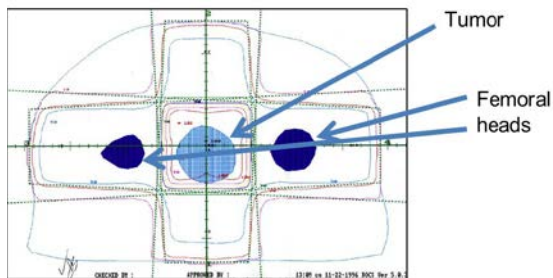


Figure 25. External beam plan, 4 field pelvis. Dose comes from AP, PA & Right and Left Lateral fields, or beam. A single axial slice, called a 2D plan. Courtesy of University of Massachusetts Medical School, Department of Radiation Oncology, UMass Memorial Medical Center.

In patients who have confirmed deep myometrial invasion (Figure 26), cervical stromal involvement, pelvic nodal or vaginal metastases, or high grade cancer after surgical staging, adjuvant therapy is usually recommended to attempt to prevent disease recurrence. Adjuvant therapy may be delivered with external beam radiotherapy

Endometrial Cancer

Richard S. Pieters, MD
Maryanne Bombaugh, MD
Yuxin Liu, MD, PhD
Gina Cunto-Amesty, MD
Adib R. Karam, MD
Elizabeth Kurian, MD
Sarah Hughes, MD



or vaginal brachytherapy. For node positive, high grade tumors, the addition of chemotherapy to adjuvant radiotherapy is under active investigation.¹⁰

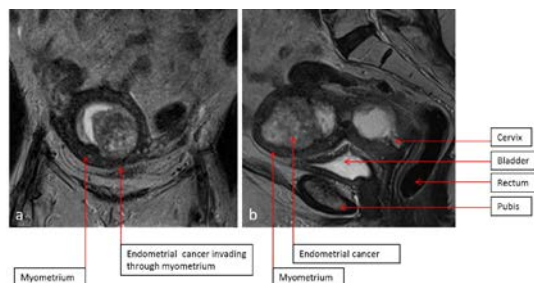


Figure 26. 51-year-old female patient with biopsy proven endometrial carcinoma. Coronal plane at the level of the uterine fundus (a) and mid-sagittal plane (b) images from pelvic MRI demonstrate a large and heterogeneous endometrial mass consistent with the biopsy proven endometrial carcinoma, extending into the endocervical canal. Note the presence of deep myometrial invasion at the level of the fundus (a). Courtesy of University of Massachusetts Medical School, Abdominal Imaging Division, UMass Memorial Medical Center

Prognosis

With modern treatment, about 90 % of patients with Stage I 80% with Stage II, 65% with Stage III, and 25% of Stage IV adenocarcinoma of the endometrium will be alive at 5 years. Older patients and patients with higher grade tumors will do less well, as will CS patients, stage for stage. Endometrial stromal sarcomas have an excellent 5 year survival.¹¹ Median survival for leiomyosarcomas is about 4 years.¹²

Conclusion

Endometrial adenocarcinoma is common. Postmenopausal vaginal bleeding is never normal and patients experiencing it must be worked up for endometrial cancer. Most patients present with early stage disease which is estrogen dependent, or Type 1, and have an excellent prognosis. Uterine sarcomas are much less common.

Endometrial Cancer

Richard S. Pieters, MD
Maryanne Bombaugh, MD
Yuxin Liu, MD, PhD
Gina Cunto-Amesty, MD
Adib R. Karam, MD
Elizabeth Kurian, MD
Sarah Hughes, MD



Leiomyosarcomas, carcinosarcomas and Type 2 endometrial cancers are more aggressive cancers and have a poorer prognosis.

Stages of endometrial cancer according to FIGO (International Federation of Gynecology and Obstetrics classification in brief).⁸

Stage 1	Tumor confined to the uterus
Stage 2	Tumor extends to the cervix
Stage 3	Tumor extends to the adjacent organs but not the bladder and rectal mucosa or involves the regional lymph nodes
Stage 4	Tumor metastasize to the distant organs

Thought Questions

1. Estrogen can increase the risk of endometrial cancer, particularly Type 1 tumors. Tamoxifen, a selective estrogen receptor modulator, lowers a post-menopausal woman's risk of developing an estrogen receptor positive breast cancer by 40%, but increases the risk of developing endometrial cancer by 300%. Think of ways that Tamoxifen can reduce the risk of an estrogen-associated cancer in one organ, but increase the risk in another.

Your answer:

[Expert Answer](#)

Endometrial Cancer

Richard S. Pieters, MD
Maryanne Bombaugh, MD
Yuxin Liu, MD, PhD
Gina Cunto-Amesty, MD
Adib R. Karam, MD
Elizabeth Kurian, MD
Sarah Hughes, MD



2. Endometrial cancer is the most common gynecologic cancer in the United States, but cervical cancer is the most common gynecological cancer in many developing countries. What reasons may contribute to differences in incidence of these cancers in different societies?

Your answer:

[Expert Answer](#)

3. Why is it believed that the incidence of endometrial cancer will increase in the future?

Your answer:

[Expert Answer](#)

Endometrial Cancer

Richard S. Pieters, MD
Maryanne Bombaugh, MD
Yuxin Liu, MD, PhD
Gina Cunto-Amesty, MD
Adib R. Karam, MD
Elizabeth Kurian, MD
Sarah Hughes, MD



Glossary

Cribriforming pattern- A sieve like histologic appearance

Nulliparity- The state of never having been pregnant

Polycystic ovary disease (Stein-Leventhal Syndrome)- An endocrine disorder with enlarged ovaries with small collections of fluid, follicles- best seen on ultrasound or CT, associated with infrequent or prolonged menses, infertility, excess hair growth, acne, and obesity.

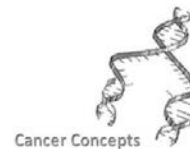
Unopposed estrogen exposure- Estrogen exposure without progesterone exposure

References

1. [Endometrial \(Uterine\) Cancer](#). American Cancer Society. Accessed 07 November 2011.
2. Jemal A, Murray T, Ward E, et al. [Cancer statistics, 2005](#). *CA Cancer J Clin*. 2005; 55(1):10–30.
[PubMed Abstract](#)
3. National Cancer Institute. Endometrial Cancer Prevention (PDQ®).
http://www.cancer.gov/cancertopics/pdq/prevention/endometrial/HealthProfessional/page2#Section_120.
4. Timmermans A, Opmeer BC, Khan KS, et al. [Endometrial thickness measurement for detecting endometrial cancer in women with endometrial bleeding](#). *Obstet Gynecol*. 2010; 116(1):160-7.
[PubMed Abstract](#)
5. Boyd J. Hereditary gynecology cancer syndromes. In: Gershenson DM, McGuire WP, Gore M, Quinn MA, Thomas G, eds. *Gynecologic Cancer: Controversies in Management*. 1st ed. Philadelphia PA: Elsevier; 2004; 833–45.
6. Kurman R, Kaminski PF, Norris H. [The behavior of endometrial hyperplasia. A long term study of “untreated” hyperplasia in 170 patients](#). *Cancer*. 1985; 56(2):403-12.
[PubMed Abstract](#)

Endometrial Cancer

Richard S. Pieters, MD
Maryanne Bombaugh, MD
Yuxin Liu, MD, PhD
Gina Cunto-Amesty, MD
Adib R. Karam, MD
Elizabeth Kurian, MD
Sarah Hughes, MD



7. American College of Obstetricians and Gynecologists. [ACOG practice bulletin, clinical management guidelines for obstetrician-gynecologists, number 65, August 2005: management of endometrial cancer.](#) *Obstet Gynecol.* 2005; 106(2):413-25.
[PubMed Abstract](#)
8. Creasman WT, Morrow CP, Bundy BN, Homesley HD, Graham JE, Heller PB. [Surgical pathological spread patterns of endometrial cancer.](#) *Cancer.* 1987; 60(S8):2035-41.
[PubMed Abstract](#)
9. D'Angelo E, Prat J. [Uterine sarcomas: a review.](#) *Gynecol Oncol.* 2010; 116(1):131-9. doi: 10.1016/j.ygyno.2009.09.023.
10. Lachance J, Darus CJ, Rice LW. [Surgical management and postoperative treatment of endometrial carcinoma.](#) *Rev Obstet Gynecol.* 2008; 1(3): 97-105.
11. Amant F, Floquet A, Friedlander M, et al. [Gynecologic Cancer InterGroup \(GCIG\) consensus review for endometrial stromal sarcoma.](#) *Int J Gynecol Cancer.* 2014; 24(9 Suppl 3):S67-72. doi: 10.1097/IGC.0000000000000205.
12. Tirumani SH, Deaver P, Shinagare AB, et al. [Metastatic pattern, predictors and outcome of 113 patients with uterine leiomyosarcoma.](#) *J Gynecol Oncol.* 2014; 25(4):306-12. doi: 10.3802/jgo.2014.25.4.306.